

Mediastinal lymph node metastasis as a single expression of disease relapse in Ewing's sarcoma: multidisciplinary approach of two consecutive cases

Filippo Tommaso Gallina^{1,*}, Virginia Ferraresi², Alessio Annovazzi³, Sabrina Vari², Paolo Visca⁴, Daniele Forcella¹, Daniela Assisi⁵, Enrico Melis¹, Francesco Facciolo¹

¹Department of Thoracic Surgery, IRCCS Regina Elena National Cancer Institute, Rome, Italy;

²Department of Medical Oncology 1, IRCCS Regina Elena National Cancer Institute, Rome, Italy;

³Nuclear Medicine Unit, IRCCS Regina Elena National Cancer Institute, Rome, Italy;

⁴Pathology Unit, IRCCS Regina Elena National Cancer Institute, Rome, Italy;

⁵Digestive Endoscopy Unit, IRCCS Regina Elena National Cancer Institute, Rome, Italy.

SUMMARY Ewing's sarcoma of the bone is a rare, highly aggressive tumor that typically affects children and young adults. Progress in the treatment of Ewing's sarcoma has improved survival from about 10%, before the introduction of chemotherapy, to about 75% today for patients with localized tumors. On the contrary, metastatic disease still has a poor prognosis, and a multidisciplinary approach is essential to improve the outcome. Molecular techniques and new imaging modalities are affecting the diagnosis and classification of patients with Ewing's sarcoma. The most frequent sites of metastases in Ewing's sarcoma include lungs, bones and bone marrow. Lymph nodes are a rare site of metastatic spread, particularly in the mediastinum. In this report, we present two consecutive cases of patients with Ewing's Sarcoma, diagnosed, and treated at our institute. We focused particularly on the rarity of the atypical presentation of the disease and on the synergistic strategy to adopt as a model of networking in treating patients with rare diseases.

Keywords Ewing's sarcoma, mediastinum, mediastinal lymphnodes, EBUS, EUS

1. Introduction

Ewing's sarcoma is a high-grade rare tumour that arises mainly from the bone (60% of cases) where it is the third most common malignancy (1). The age of peak incidence for Ewing's sarcoma is 15 years; men are slightly more affected than women with a ratio of 3:2. Ewing's sarcoma is predominantly observed in populations of Europe (~ 1.5 cases per million children, adolescents and young adults). On the other hand, people of Asia and Africa are less affected (~ 0.8 and ~ 0.2 cases per million per year, respectively) (2).

In the era of precision medicine, many investigations and molecular testing have attempted to search new prognostic factors in order to find a specific treatment for these types of tumors (3). Treatment of Ewing's sarcoma foresees a multidisciplinary approach including systemic aggressive polichemotherapy regimens and local therapy (surgery and/or radiotherapy for unresectable primitive sites or metastases) (4,5). Approximately 25% of patients with Ewing's sarcoma are diagnosed with advanced disease where typically the lung is the most

frequent metastatic site at diagnosis or at the moment of relapse (6). Other typical sites of metastases are the bone and bone marrow and in cases of suspicious lesions biopsies should be performed. In cases of multiple metastases, prognosis is generally poor. A small percentage of metastatic patients can however, still achieve lasting control of disease with combined therapeutic approaches including chemotherapy and radiotherapy on bulky disease or surgery on selected metastatic sites (7). Despite the lack of prospective studies aimed at evaluating the role of clinical and radiological surveillance in high-grade sarcomas, the prognostic value of early detection of local recurrence or distance metastases is recognized and a regular follow up policy is strongly recommended. Lymph node metastases of Ewing's sarcoma are extremely rare and there are still no cases of mediastinal lymph nodes as a single disease relapsing reported in the literature. In this report, we present two cases of patients with Ewing's sarcoma who showed a single recurrence on mediastinal lymph nodes on CT and FDG PET/CT, that were histologically confirmed *via* thoracic endoscopy. Before writing this

case report, we have obtained an informed consent from the patients.

2. Case Report

2.1. Case 1

A 32-year old male patient was admitted to our thoracic endoscopy unit. In January 2016, he was initially diagnosed with Ewing's Sarcoma of the right hip. The patient was enrolled in ISG-AIEOP EW1 (EudraCT: 2008-008361-35), arm B, a clinical trial and received neoadjuvant chemotherapy consisting of a VAI (vincristine, adriamycin, and ifosfamide) regimen for 4 courses. In May 2016, he underwent a resection of the right hip where the histological examination showed a pathological complete response. After surgery, he was treated as per *good responder* maintenance phase of the arm with VAI for 1 cycle and IE (ifosfamide and etoposide) for 4 cycles until October 2016. Subsequently, the patient underwent a physical examination, pelvis MRI and thorax CT scan every 4 months until September 2019, when a ^{18}F -FDG PET/CT scan showed a moderate FDG uptake ($\text{SUV}_{\text{max}} = 3.7$) in a small mediastinal left peri-bronchial lymph node, suspicious for metastasis (Figure 1A). A contrast enhanced CT scan (Figure 1B) performed one month later showed a significant increase in the size of the lymph node (28 vs. 15 mm). After some discussion at the sarcoma disease management team meeting, an endoscopic ultrasound fine needle aspiration biopsy was decided to be performed (EUS-FNAb). After deep sedation with propofol was induced by using an echo-endoscope, an examination of all

mediastinal lymph node stations was performed. In correspondence to station 8, a hypoechoic mass was found and an FNA was performed with a 22G Cook needle (Figure 2A). We obtained samples for cytological and histological examinations, both confirming a relapse of Ewing's sarcoma (Figure 2B). Immunohistochemical analysis showed a CD99+, CD45- and CKMNF116-, molecular analysis presented a EWSR11-FLI1 fusion transcript. The patient was then enrolled in a rEECur randomized clinical trial for metastatic disease (EudraCT number: 2014-000259-99), randomized in Topotecan plus a Cyclophosphamide (TC) arm, where he is still in treatment. The best response obtained after 2 cycles was partial, and the last CT scan showed an unvarying response. The patient has received 6 cycles of chemotherapy and is currently waiting for a CT re-evaluation of disease. Local treatment (radiotherapy or surgery) will be considered upon confirmation of response and chemotherapy might be continued until disease progression or severe toxicities.

2.2. Case 2

We evaluated a 74-year old male patient with hypertension and a history of stroke anamnesis. In May 2013, he noticed a persistent swelling of the left arm. For this reason, he underwent a biopsy, with a Ewing's Sarcomas diagnosis. The patient had 3 cycles of neoadjuvant chemotherapy with Epirubicin, Cyclophosphamide and Vincristine, and in December 2013 the patient's lesion underwent radical surgery, with 30% necrosis. He subsequently received 4 cycles of adjuvant chemotherapy with IE until May 2014. In

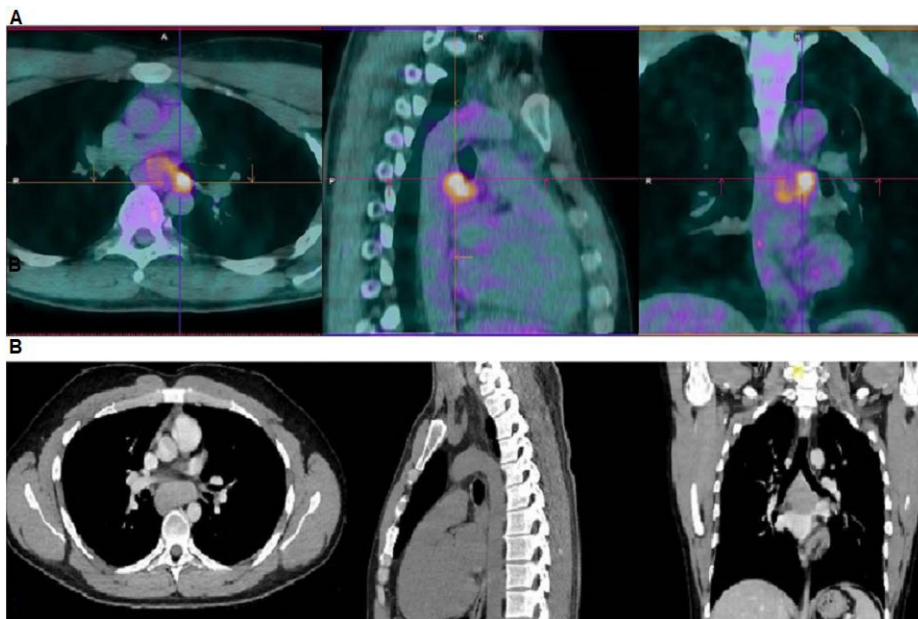


Figure 1. (A) Axial (left), sagittal (middle) and coronal (right) ^{18}F -FDG PET/CT fused views in a patient with Ewing sarcoma. A PET/CT performed during follow up showed a focal area of moderate FDG uptake ($\text{SUV}_{\text{max}} = 3.7$) in a small left para-esophageal lymph node, suspected for metastasis. (B) A contrast enhanced CT scan (Figure 1b) performed one month later showed a significant increase in the size of the lymph node (28 vs. 15 mm). The metastatic origin of the lymph node was then confirmed by transbronchial needle aspiration.

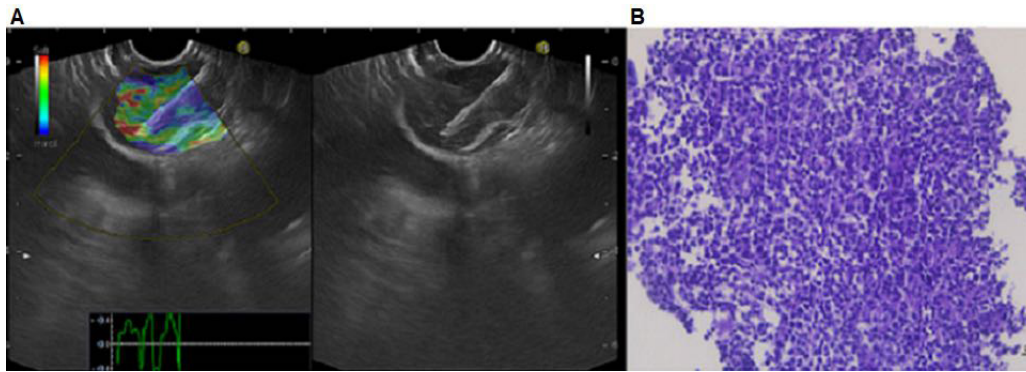


Figure 2. (A) Endoscopic ultrasound with elastography of the hypoechoic lymph node aspiration with 22G needle in correspondence of the paraoesophageal station. The elastography showed a predominantly blue pattern suspected for malignant lymph node. (B) Undifferentiated small round cell neoplasm consisting of relative monomorphic elements cohesive with hyperchromic nuclei and poor eosinophilic cytoplasm (All images are 20× magnification).

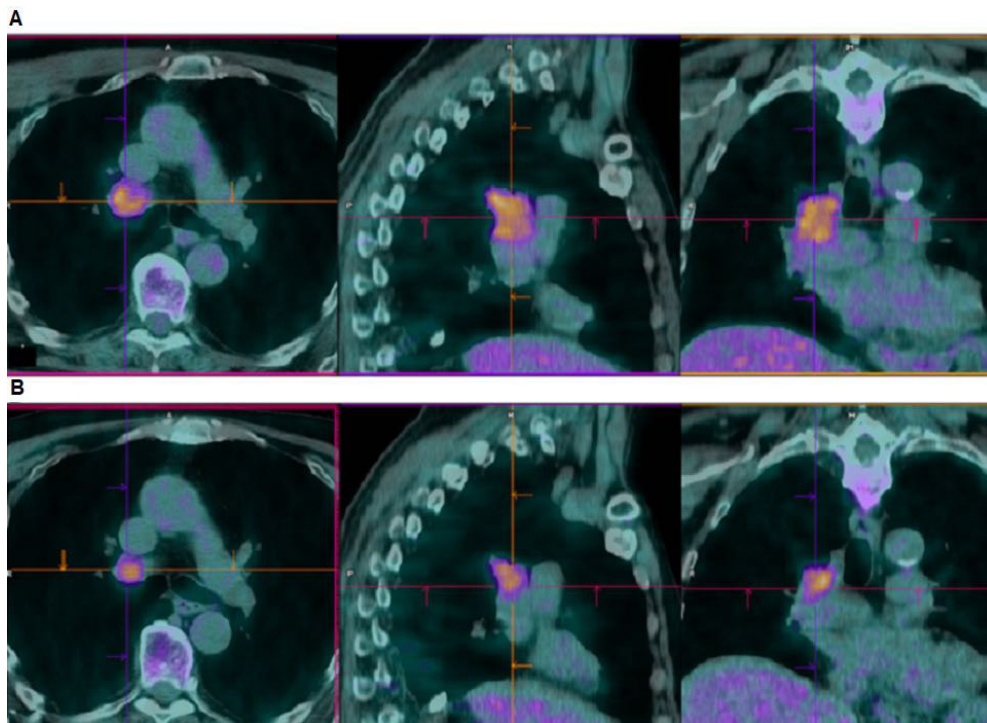


Figure 3. (A) Axial (left), sagittal (middle) and coronal (right) ^{18}F -FDG PET/CT fused views in a patient with Ewing sarcoma. A PET/CT performed during follow up showed an intense FDG uptake (SUVmax = 7.1) in a single right tracheobronchial metastatic lymph node (histologically confirmed). (B) A second PET/CT scan performed four months later undergoing chemotherapy revealed a significant reduction of the lymph node size (Metabolic Tumor Volume 10.8 vs. 32.4 cc), despite a persistently high FDG uptake (SUVmax = 7.2).

March 2019, the patient was admitted to right upper lobe wedge resection for a single pulmonary metastasis. An ^{18}F -FDG PET/CT scan performed for restaging in December 2019 showed high focal FDG uptake in a 26 × 33 mm mediastinal lymphadenopathy, station 4R (lower paratracheal lymph nodes) (Figure 3A). After having held an oncological multidisciplinary meeting, an endobronchial ultrasound with a transbronchial needle aspiration biopsy (EBUS-TBNA) was decided to be carried out. The exam was performed under deep sedation with propofol and local oral anaesthesia. After inserting the echo-bronchoscope, we evaluated all

mediastinal stations and in correspondence to the right lower paratracheal station, we found a hypoechoic lesion that crossed the limit of station 10R with no evidence of clear cleavage plane. We performed a TBNA with a 22G Cook needle and obtained enough tissue sampling for cytological and histological examinations (Figure 4A). The histopathological response was consistent with a Ewing's sarcoma metastatic lymph node and the immunohistochemical analysis showed a CD99+, CD45- and CKMNF116- (Figure 4B). The molecular analysis confirmed the diagnosis showing a EWSR11-FLI1 fusion transcript. Since January 2020, the patient has been

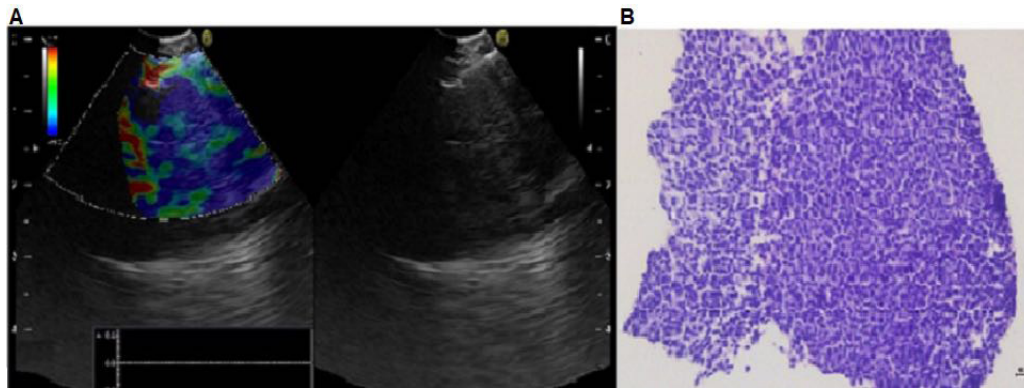


Figure 4. (A) Endobronchial ultrasound with elastography of the hypoechoic lymph node aspiration with a 22G needle in correspondence of the right lower paratracheal station and right hilar station. The elastography showed a predominantly blue pattern suspected for malignant lymph node. (B) Undifferentiated small round cell neoplasm consisting of relative monomorphic elements cohesive with hyperchromatic nuclei and poor eosinophilic cytoplasm (All images are 20× magnification).

treated with first-line chemotherapy using Temozolomide and Irinotecan (TEMIRI regimen), attenuated for age and comorbidities. Despite a dose reduction, the patient reported irinotecan related gastrointestinal toxicity (persistent grade 2 diarrhoea) requiring intravenous fluid supplementation, leading to drug discontinuation. The patient-maintained treatment with temozolomide as a single agent obtaining a metabolic stabilization of the disease at first re-evaluation of disease in April 2020 (Figure 3B).

3. Discussion

The prognosis for patients with metastatic Ewing's sarcoma is generally poor (1). Despite aggressive systemic and local therapies, a small percentage of patients can still achieve long-term disease control, depending on time to relapse and extension and sites of metastatic disease. Lung and pleural metastases show in fact better prognosis compared to patients with bone metastases and bone marrow involvement.

Even though a standardized surveillance policy has not yet been approved in high-grade sarcomas, accepted and well established guidelines indicate that locoregional imaging using MRI and chest X-ray/CT should be carried out after completing chemotherapy for localized disease approximately every 3 months for the first 2 years; every 6 months for years 3-5, every 6-12 months for years 5-10, and thereafter every 0.5-2 years. Specifically, in Ewing's sarcoma and other bone sarcomas, bone scan imaging was also extensively used in patient follow ups due to its high accuracy for the detection of bone metastases. More recently, techniques such as ^{18}F -FDG PET/CT or whole-body MRI are increasingly being adopted into routine practice but require further evaluation in clinical trials (8).

Metastases on lymph nodes are extremely rare, especially in the mediastinum. After all, searching on PubMed using the keywords "Ewing's sarcoma relapse", "Ewing's sarcoma lymph node", "mediastinal Ewing's sarcoma relapse" and "metastatic Ewing's sarcoma",

there are only a few cases of metastatic lymph nodes reported in the literature. Weshi *et al.* in an analysis of 57 patients with extra skeletal Ewing's sarcoma, reported five cases of primary lymph node disease and only one patient with first relapse on lymph nodes (9). Somarouthu *et al.* reported the clinical outcomes of 26 patients with extra skeletal Ewing's sarcoma where 4 patients presented lymph node metastatic disease (10). In a retrospective study of a single institution, Huh *et al.* presented 5 patients with metastatic disease in mediastinal lymph nodes. The authors reported that lymph node metastases were commonly found in patients with primary extra-skeletal Ewing's sarcoma of the torso, including the abdomen, lung, peritoneum, pleura, and paravertebral region, compared to patients affected with the disease on the extremities, head, and neck (11).

The peculiarity of the cases described herein is that both patients with skeletal Ewing's sarcoma presented a mediastinal lymphadenopathy PET positive as a single localization of disease relapse. Our patients presented the primary tumor on the left arm and on the right hip. Both patients presented a single disease relapse in a single mediastinal lymph node station. We considered this condition to be metastatic disease and they were treated with an appropriate chemotherapy regimen. The first follow up after the treatment of the relapsing disease showed a partial response for patient 1 and metabolic stability for patient 2. In regard to the poor prognosis of metastatic Ewing's sarcoma, we can therefore consider the response to treatment satisfying. To our knowledge, there are no similar cases described in the literature.

The use of ^{18}F -FDG PET/CT has been shown to be helpful in the initial evaluation, restaging and monitoring treatment response in patients with Ewing Sarcoma (12). In particular, PET-CT plays an important role in detection of bone metastases, showing a more accurate detection than bone scintigraphy. The presence of FDG-positive lymph nodes on PET/CT scan should be evaluated carefully for possible false positive findings due to inflammation. A different approach was carried

out for the two patients: in case 1, due to a moderate FDG uptake, we required a short-term CT evaluation to confirm a suspicious lymph node. In case 2, an intense FDG uptake suggested a possible metastasis so we proceeded to directly carry out a histological confirmation.

Thoracic endoscopy is the safest and most feasible technique to evaluate the mediastinum and should be used when staging lung cancer patients and investigating suspected extra-thoracic cancer relapse (13). In our patients, we used EUS-FNA for subcarinal station, whereas, for right lower paratracheal stations and right hilum station EBUS-TBNA it is mandatory. By using these mini-invasive techniques, we can sample enough material to perform a quick histological and cytological diagnosis and start appropriate multimodality therapy (14). Compared to mediastinoscopy, EBUS-TBNA and EUS-FNA are less invasive and can be performed in an outpatient regimen with moderate sedation (15). The association between EBUS and EUS allows improvement of the quality standard of diagnosis in terms of sensitivity, specificity, and accuracy. Only a few patients needed surgery to achieve the mediastinal lymph node biopsy. One of the main limitations of these types of procedures is that their accuracy strongly depends on the operator's skills.

There are no standardized chemotherapy regimens to treat recurrent Ewing's sarcoma (16,17). In the immunotherapy era, there are currently in progress few clinical trials assessing checkpoint inhibitors that interrupt the repressive crosstalk between cancer and immune cells, either as a single agent or combined with conventional chemotherapy (18). Unfortunately, clinical responses in trials remain anecdotal but highlight the necessity to improve characterization of the tumor micro-environment to unlock the immunotherapeutic response (19). Despite novel therapeutic strategies for Ewing's sarcoma that include IGF-1 receptor (IGF-1R)-targeted antibodies combined with mTOR inhibitors (mTORi), as well as chemotherapy-PARP combinations, which could represent new prospects for the future, the prognosis remains poor (20,21).

Treating elderly patients with Ewing's sarcoma is really challenging due to greater aggressiveness and toxicity of the chemotherapy regimens that prove to be effective in the younger population, as well as a lack of prospective clinical trials evaluating this extremely rare subpopulation of patients. Despite very good clinical conditions and a 25% dose reduction from the first cycle of the TEMIRI regimen, our 74-year old patient was not able to tolerate the combination of drugs and therefore continued with oral temozolomide alone.

When a very rare disease presents itself, as demonstrated by our two patients, a synergistic strategy should be put into place by giving the patient the best therapeutic options. This strategy is mainly made up of three steps. First, a strict follow-up is conducted by the

oncologist in accordance with international guidelines. Second, an imaging evaluation by a dedicated nuclear medicine doctor is performed. Third, an accurate and fast diagnosis using less invasive thoracic endoscopic techniques and a histological examination are carried out. All these steps lead to the beginning of a personalized therapeutic course based on patient characteristics using the most innovative therapy protocols. The therapeutic algorithm for single site relapse of Ewing's sarcoma is not well defined. A multidisciplinary discussion in centers with high expertise on Ewing's sarcoma is absolutely required for a correct diagnosis and therapy of the patient with single site lymph node metastasis to offer treatment with potentially still curative intentions.

In conclusion, although very rare, mediastinal lymph node relapsing should always be considered in cases of radiological suspicion. If lymph nodes are the only suspicious site of metastatic disease on a CT or PET/CT scan, a histological examination should quickly be carried out in order to exclude inflammatory diseases like sarcoidosis or other neoplastic conditions.

Acknowledgements

The authors want to thank the Scientific Direction of the IRCCS "Regina Elena" National Cancer Institute for support of our work. There are no conflicts of interest.

Funding: None.

Conflict of Interest: The authors have no conflicts of interest to disclose.

References

1. Grünewald TGP, Cidre-Aranaz F, Surdez D, Tomazou EM, de Álava E, Kovar H, Sorensen PH, Delattre O, Dirksen U. Ewing sarcoma. *Nat Rev Dis Primers*. 2018; 4:5.
2. Balamuth NJ, Womer RB. Ewing's sarcoma. *Lancet Oncol*. 2010; 11:184-192.
3. Casey DL, Lin TY, Cheung NV. Exploiting signaling pathways and immune targets beyond the standard of care for Ewing sarcoma. *Front Oncol*. 2019;9:537.
4. Gaspar N, Hawkins DS, Dirksen U, *et al*. Ewing sarcoma: Current management and future approaches through collaboration. *J Clin Oncol*. 2015; 33:3036-3046.
5. Haeusler J, Ranft A, Boelling T, Gosheger G, Braun-Munzinger G, Vieth V, Burdach S, van den Berg H, Juergens H, Dirksen U. The value of local treatment in patients with primary, disseminated, multifocal Ewing sarcoma (PDMES). *Cancer*. 2010; 116:443-450.
6. Scurr M, Judson I. How to treat the Ewing's family of sarcomas in adult patients. *Oncologist*. 2006; 11:65-72.
7. Stahl M, Ranft A, Paulussen M, Bölling T, Vieth V, Bielack S, Görtitz I, Braun-Munzinger G, Harges J, Jürgens H, Dirksen U. Risk of recurrence and survival after relapse in patients with Ewing sarcoma. *Pediatr Blood Cancer*. 2011; 57:549-553.
8. Casali PG, Bielack S, Abecassis N, *et al*. Bone sarcomas:

- ESMO-PaedCan-EURACAN Clinical Practice Guidelines for diagnosis, treatment and follow-up. *Ann Oncol*. 2018; 29(Suppl 4):iv79-iv95.
9. El Weshi A, Allam A, Ajarim D, Al Dayel F, Pant R, Bazarbashi S, Memon M. Extraskeletal Ewing 's sarcoma family of tumours in adults : Analysis of 57 patients from a single institution. *Clin Oncol (R Coll Radiol)*. 2010; 22:374-381.
 10. Somarouthu BS, Shinagare AB, Rosenthal MH, Tirumani H, Hornick JL, Ramaiya NH, Tirumani SH. Multimodality imaging features, metastatic pattern and clinical outcome in adult extraskeletal Ewing sarcoma: experience in 26 patients. *Br J Radiol*. 2014; 87:20140123.
 11. Huh J, Kim KW, Park SJ, Kim HJ, Lee JS, Ha HK, Tirumani SH, Ramaiya NH. Imaging features of primary tumors and metastatic patterns of the extraskeletal Ewing sarcoma family of tumors in adults: A 17-year experience at a single institution. *Korean J Radiol*. 2015; 16:783-790.
 12. Costelloe CM, Chuang HH, Daw NC. PET/CT of osteosarcoma and Ewing sarcoma. *Semin Roentgenol*. 2017; 52:255-268.
 13. Annema JT, Versteegh MI, Veselić M, Voigt P, Rabe KF. Endoscopic ultrasound-guided fine-needle aspiration in the diagnosis and staging of lung cancer and its impact on surgical staging. *J Clin Oncol*. 2005; 23:8357-8361.
 14. Sakairi Y, Nakajima T, Yoshino I. Role of endobronchial ultrasound-guided transbronchial needle aspiration in lung cancer management. *Expert Rev Respir Med*. 2019; 13:863-870.
 15. Call S, Obiols C, Rami-Porta R. Present indications of surgical exploration of the mediastinum. *J Thorac Dis*. 2018; 10(Suppl 22):S2601-S2610.
 16. Hunold A, Weddeling N, Paulussen M, Ranft A, Liebscher C, Jürgens H. Topotecan and cyclophosphamide in patients with refractory or relapsed Ewing tumors. *Pediatr Blood Cancer*. 2006; 47:795-800.
 17. Ferrari S, del Prever AB, Palmerini E, Staals E, Berta M, Balladelli A, Picci P, Fagioli F, Bacci G, Vanel D. Response to high-dose ifosfamide in patients with advanced/recurrent Ewing sarcoma. *Pediatr Blood Cancer*. 2009; 52:581-584.
 18. Heymann MF, Schiavone K, Heymann D. Bone sarcomas in the immunotherapy era. *Br J Pharmacol*. 2021; 178:1955-1972.
 19. Guven DC, Kilickap S, Yildirim HC, Ceylan F, Bas O, Dizdar O. Chemoimmunotherapy for the salvage treatment of Ewing sarcoma: A case report. *J Oncol Pharm Pract*. 2021; 27:1281-1283.
 20. Amin HM, Morani AC, Daw NC, *et al*. IGF-1R/mTOR Targeted Therapy for Ewing Sarcoma: A Meta-Analysis of Five IGF-1R-Related Trials Matched to Proteomic and Radiologic Predictive Biomarkers. *Cancers (Basel)*. 2020; 12:1768.
 21. van Maldegem AM, Bovée JV, Peterse EF, Hogendoorn PC, Gelderblom H. Ewing sarcoma: The clinical relevance of the insulin-like growth factor 1 and the poly-ADP-ribose-polymerase pathway. *Eur J Cancer*. 2016; 53:171-180.
- Received April 18, 2021; Revised July 15, 2021; Accepted July 27, 2021.
- *Address correspondence to:*
 Filippo Tommaso Gallina, Thoracic Surgery, National Cancer Institute "Regina Elena" Rome Via Elio Chianesi 53, 00144 Rome, Italy.
 Email: filippo.gallina@ifso.gov.it
- Released online in J-STAGE as advance publication August 5, 2021.